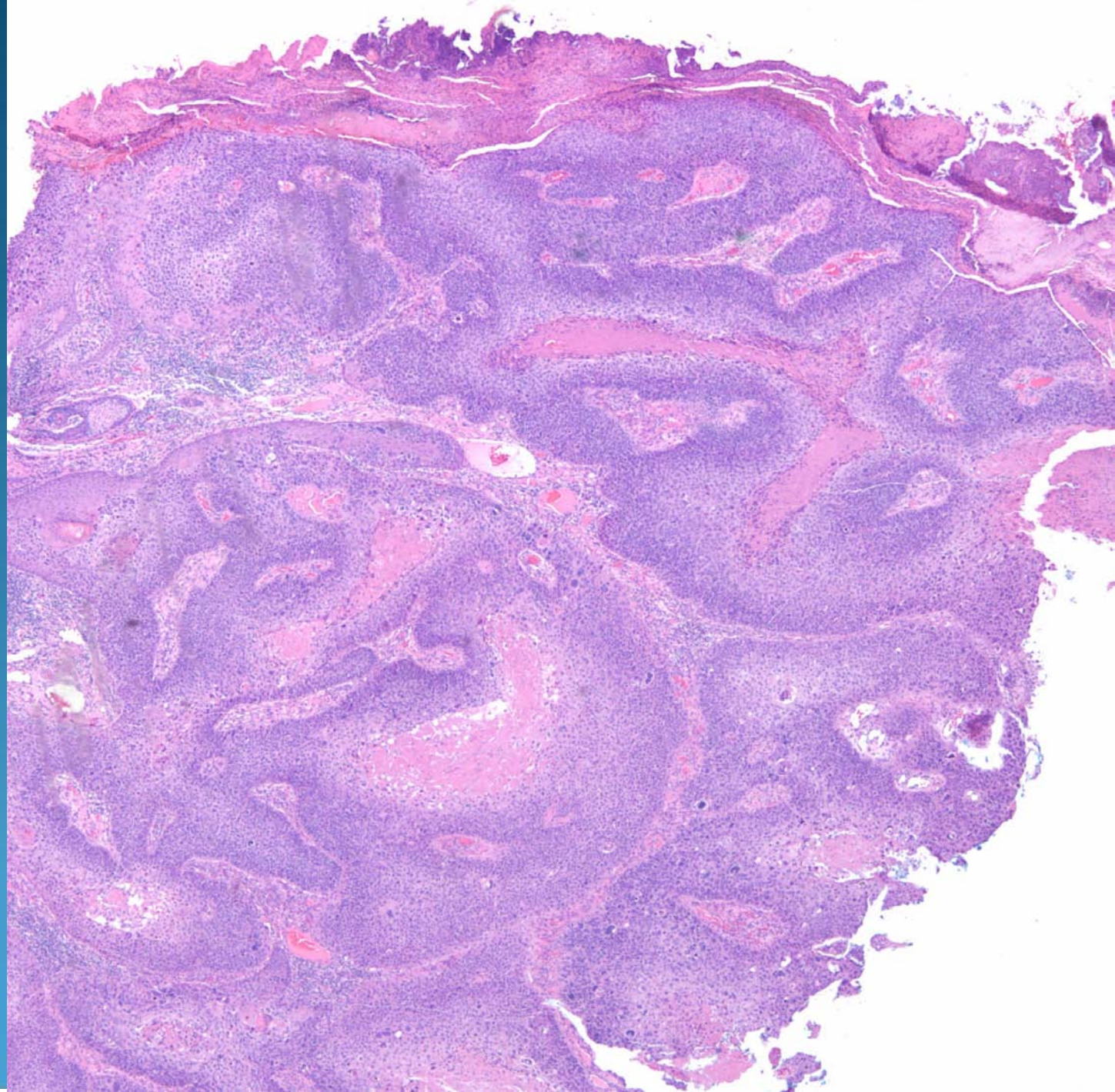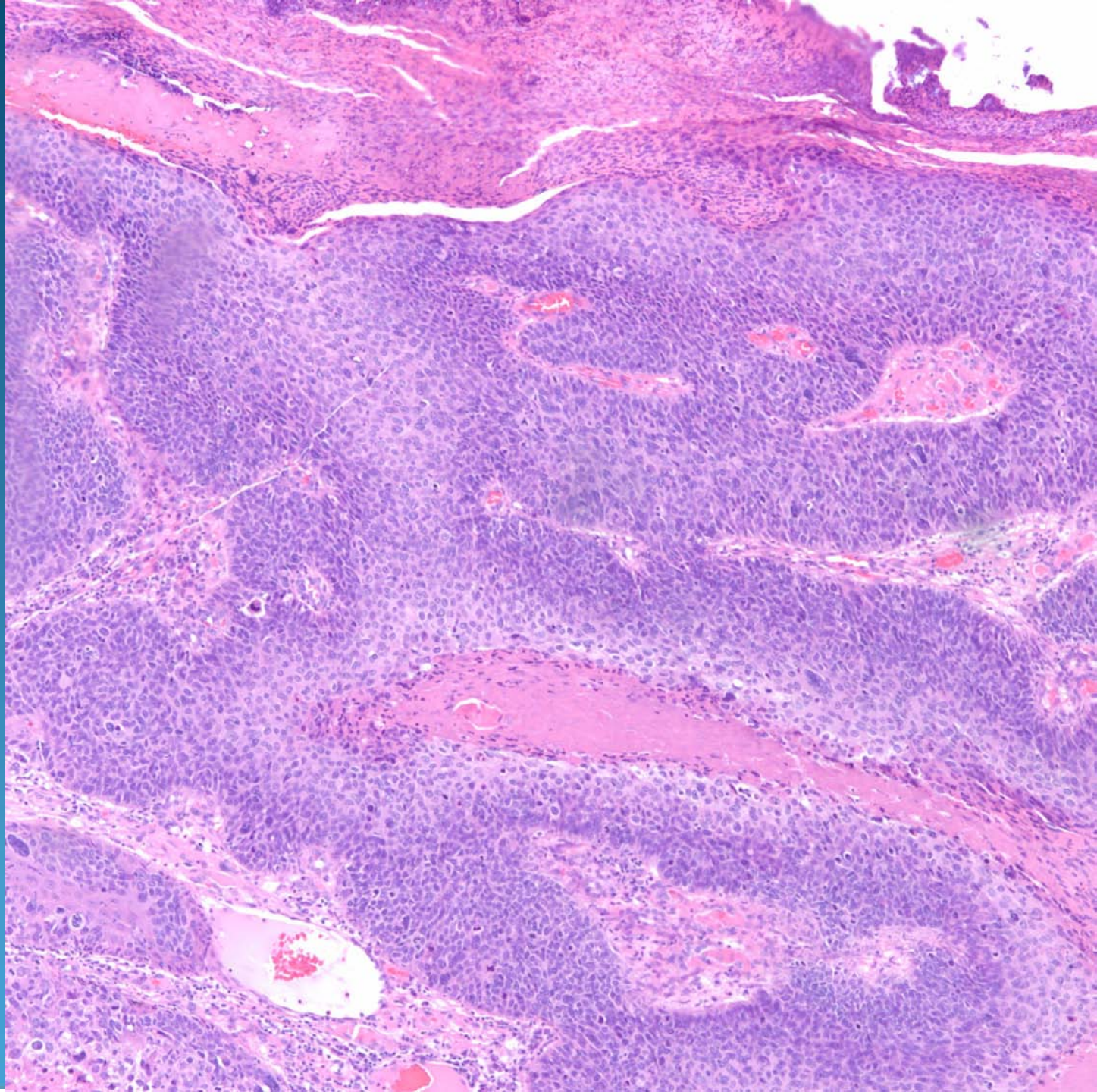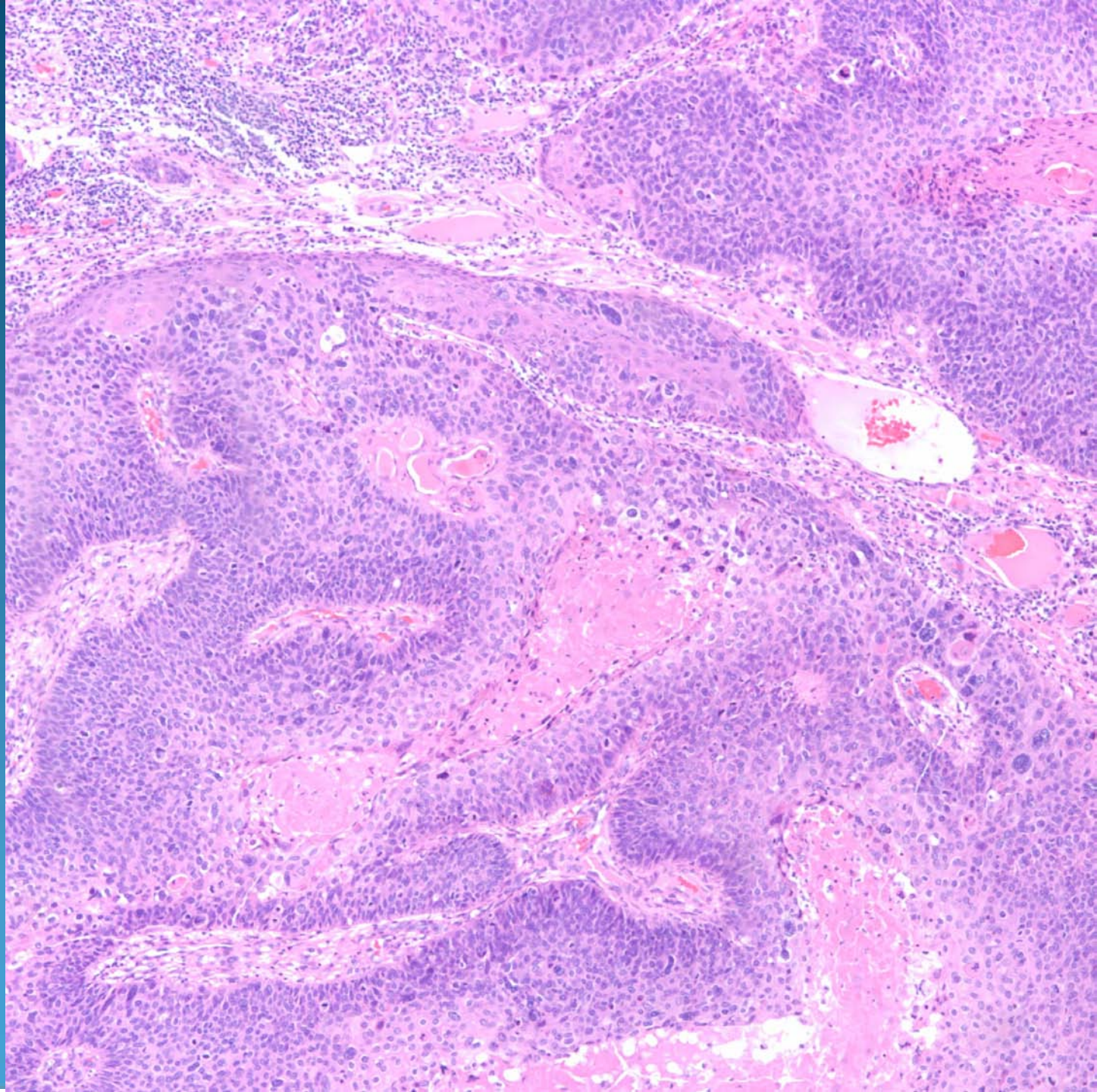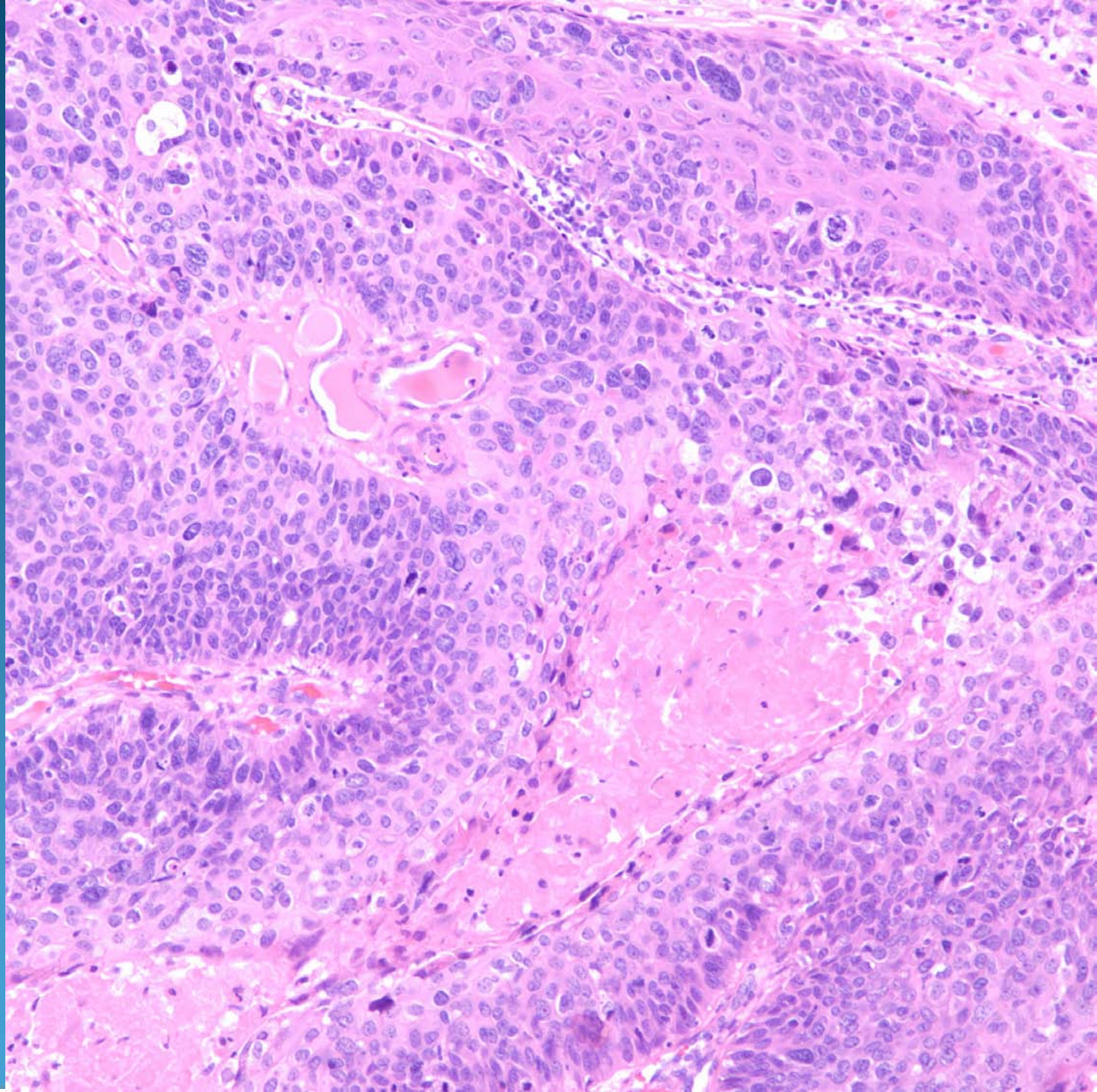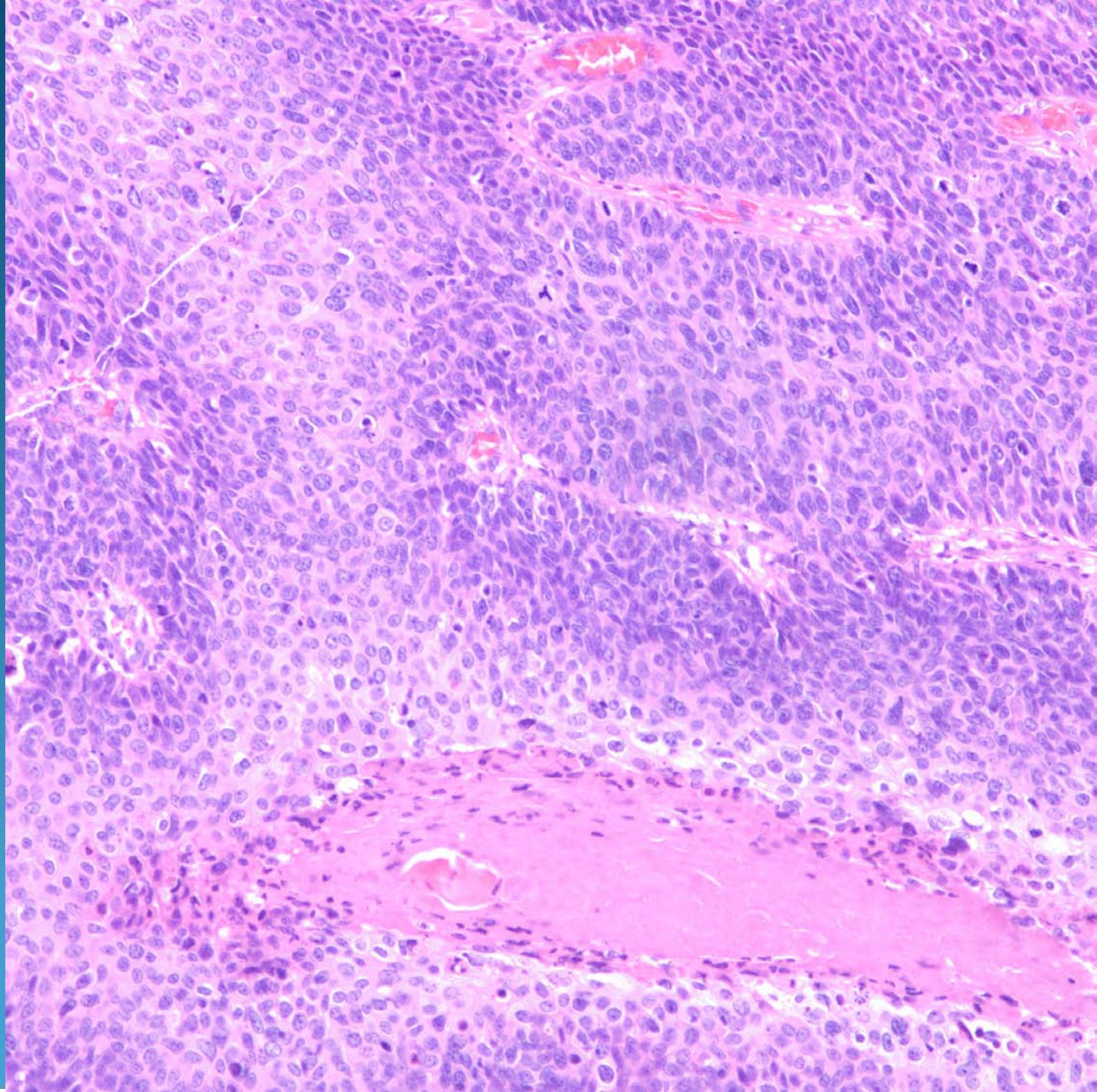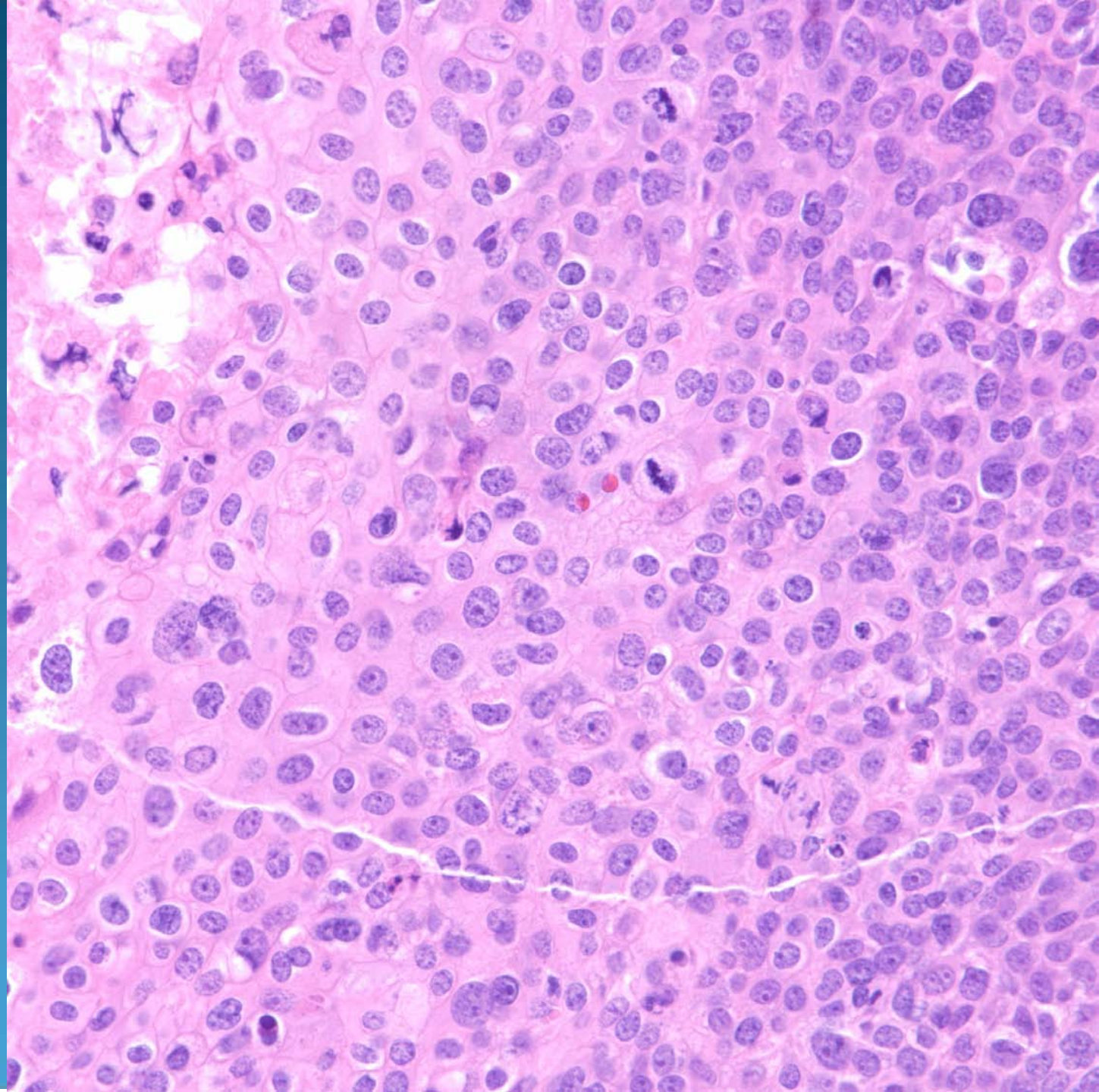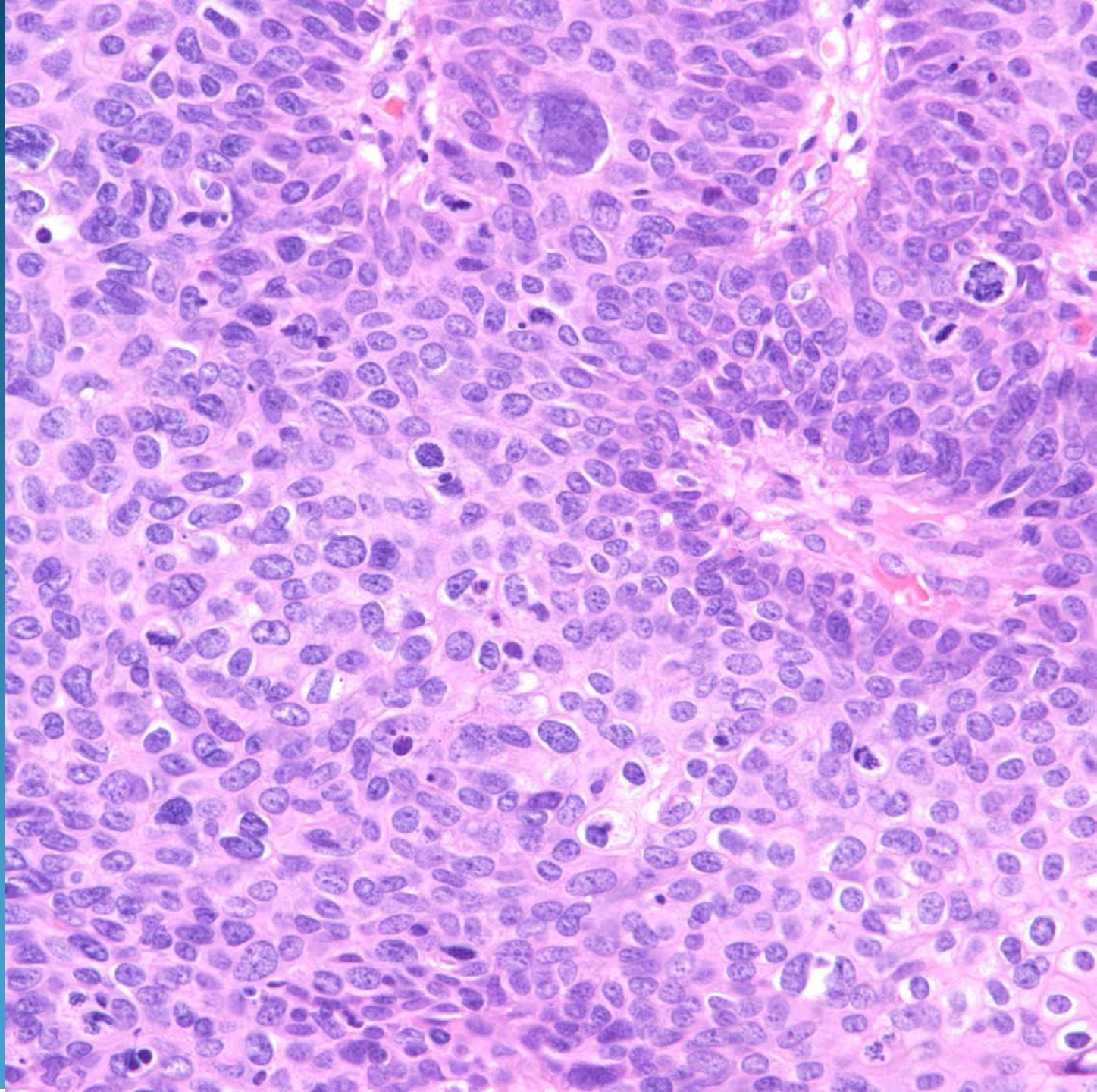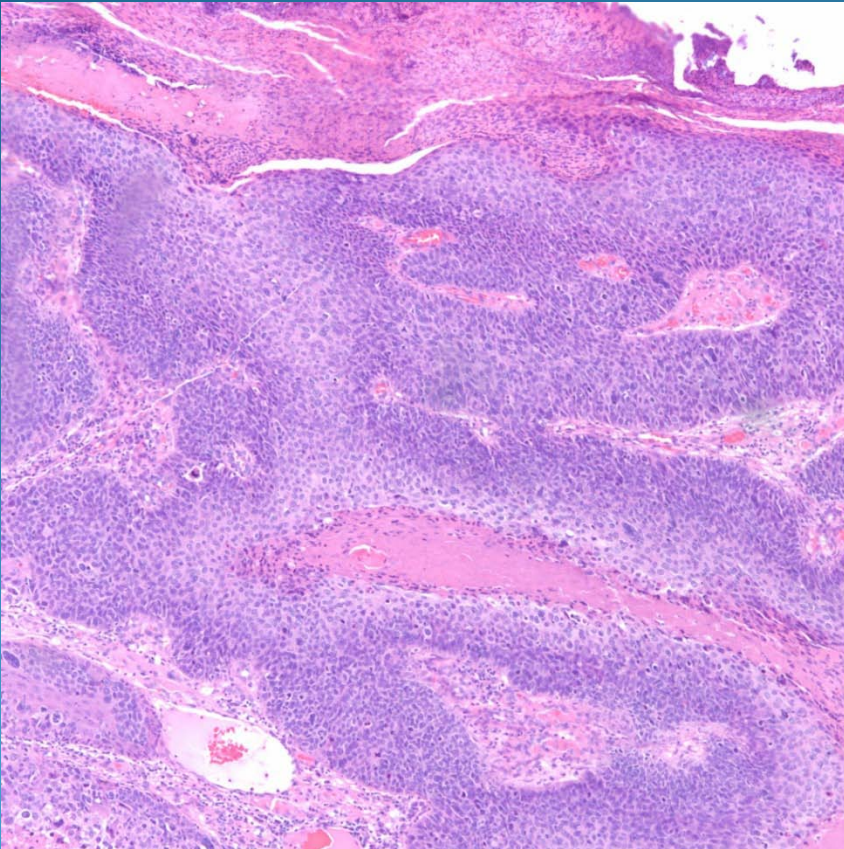


Invasive Bowenoid Squamous Cell Carcinoma

Pearls



- Epidermis replaced by full thickness atypical squamous cells (Bowen's disease)
- Epidermis in continuity with invasive nests
- High grade pleomorphic nuclei